

The structural neuroanatomy of music emotion recognition

Evidence from frontotemporal lobar degeneration.

Omar R(1), Henley SM, Bartlett JW, Hailstone JC, Gordon E, Sauter DA, Frost C, Scott SK, Warren JD.

Author information:

(1)Dementia Research Centre, Institute of Neurology, University College London, London, UK.

Citation:

Omar R, et al. (2011) The structural neuroanatomy of music emotion recognition: Evidence from frontotemporal lobar degeneration. *NCBI.Neuroimage*. 2011 June 1; 56(3): 1814–1821.

DOI: 10.1016/j.neuroimage.2011.03.002

Despite growing clinical and neurobiological interest in the brain mechanisms that process emotion in music, these mechanisms remain incompletely understood.

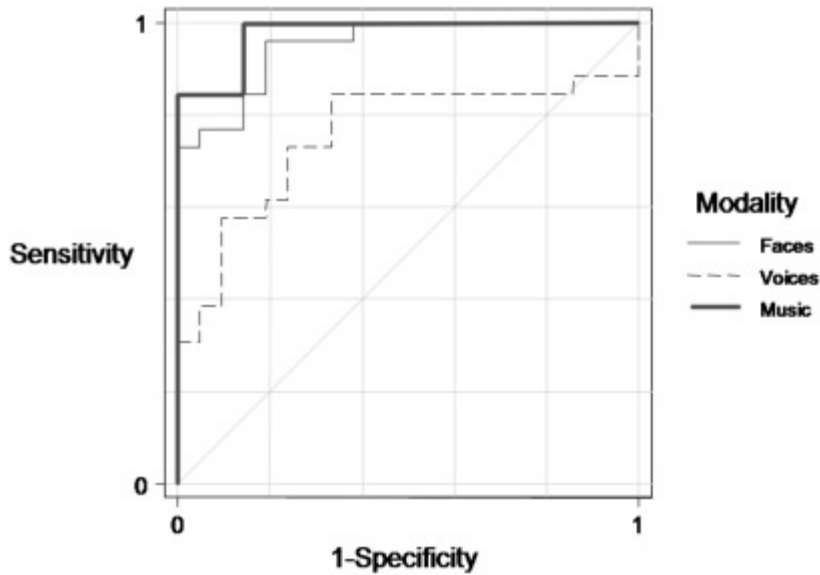
Patients with frontotemporal lobar degeneration (FTLD) frequently exhibit clinical syndromes that illustrate the effects of breakdown in emotional and social functioning.

Here we investigated the neuroanatomical substrate for recognition of musical emotion in a cohort of 26 patients with FTLD (16 with behavioral variant frontotemporal dementia, bvFTD, 10 with semantic dementia, SemD) using voxel-based morphometry.

On neuropsychological evaluation, patients with FTLD showed deficient recognition of canonical emotions (happiness, sadness, anger and fear) from music as well as faces and voices compared with healthy control subjects. Impaired recognition of emotions from music was specifically associated with grey matter loss in a distributed cerebral network including insula, orbitofrontal cortex, anterior cingulate and medial prefrontal cortex, anterior temporal and more posterior temporal and parietal cortices, amygdala and the subcortical mesolimbic system. This network constitutes an essential brain substrate for recognition of musical emotion that overlaps with brain regions previously implicated in coding emotional value, behavioral context, conceptual knowledge and theory of mind. Musical emotion recognition may probe the interface of these processes, delineating a profile of brain damage that is essential for the abstraction of complex social emotions.

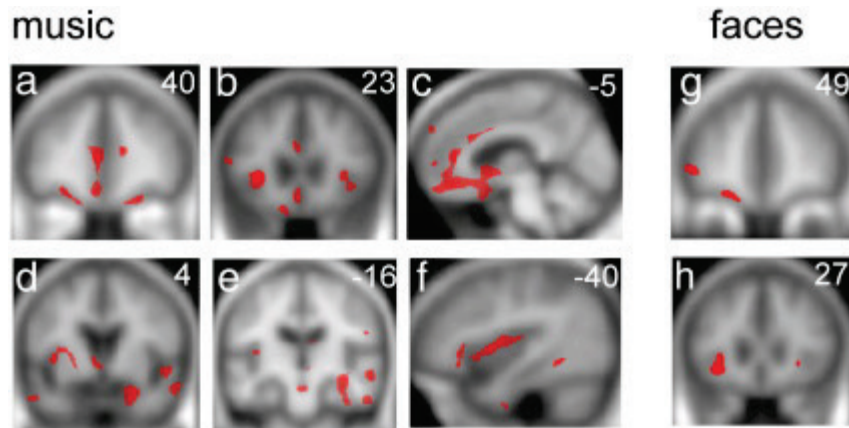
See Figures 1 and 2, next page.

Fig. 1



Comparison of emotion recognition in different modalities: prediction of disease by emotion recognition performance. The covariate (age, gender, and years of education) adjusted ROC curves use total emotion recognition scores (/40) in each modality to discriminate between FTLD patients (ignoring subtype) and controls.

Fig. 2



Statistical parametric maps (SPMs) of grey matter loss associated with impaired emotion recognition from music and faces in FTLD. Maps are based on separate-modality regression analyses (see [Methods](#)). SPMs are presented on sections of the mean normalised T1-weighted structural brain image in MNI stereotactic space; the left hemisphere is on the left and slice coordinates in mm are shown. For music, SPMs are thresholded at $p < 0.05$ FDR corrected for multiple comparisons over the whole brain volume; for faces, SPMs are thresholded at $p < 0.001$ uncorrected for display purposes. The SPMs for music and face emotion recognition show common regional grey matter associations in anterior insula (b,h) and lateral orbitofrontal cortex (a,g). In addition, the SPM for music emotion recognition shows grey matter associations in anterior cingulate (b,c), medial prefrontal cortex (a,c), anterior and superior temporal cortices (d,e,f), fusiform and parahippocampal gyri (e,f), more posterior parietal cortices (e), limbic areas including amygdala and hippocampus (d,e), and other subcortical structures including nucleus accumbens (c,d) and ventral tegmentum (e).

1. Neuroimage. 2011 Jun 1;56(3):1814-21. doi: 10.1016/j.neuroimage.2011.03.002.
Epub 2011 Mar 6.

PMCID: PMC3092986

PMID: 21385617[PubMed - indexed for MEDLINE]